

Non-Langerhans Cells Histiocytosis: An Atypical Case

Catarina Cordeiro¹, Filipa Falcão², Ana Maria Fagundo², Leonor Ramos³

Port J Pediatr 2021;52:148-9

DOI: <https://doi.org/10.25754/pjp.2021.19924>

A 4-month-old healthy boy was referred by primary health care services to our dermatology unit due to multiple progressively increasing congenital lesions in the left sternal region and in the left nasal wing. His parents denied any other symptoms, e.g. fever, anorexia, or weight loss or respiratory, gastrointestinal, or urinary complaints. A physical examination revealed multiple firm well-defined indurated erythematous and violaceous papular lesions in the left sternal region of about 6-7 mm each (Fig. 1) and smaller lesions on the left wing of the nose. There was no ocular involvement. The skin biopsy (Fig. 2) revealed the massive infiltration of the dermis by histiocytic cells, with epithelioid and fusiform morphology, arranged in bundles and nodules, separated by hyaline collagen. In addition, multiple scattered Touton-type multinucleated giant cells were distinguished. An immunohistochemical study revealed positivity for CD68 and CD163. Protein S100, CD1A, and Langerin revealed only rare scattered dendritic cells. The diagnosis of non-Langerhans cells histiocytosis was

made. No analytical study was done, and no therapy was instituted.

After 10 months of follow-up, the lesions of the nose were virtually imperceptible and the lesions in the sternal region became flat and yellowish (Fig. 3).

Non-Langerhans cells histiocytosis is a rare and heterogeneous group of diseases that require a high level of suspicion for the diagnosis. In this case, the most likely diagnosis is juvenile xanthogranuloma, which usually regresses spontaneously after a few months or years, and no further therapeutic measures are required¹⁻⁵.

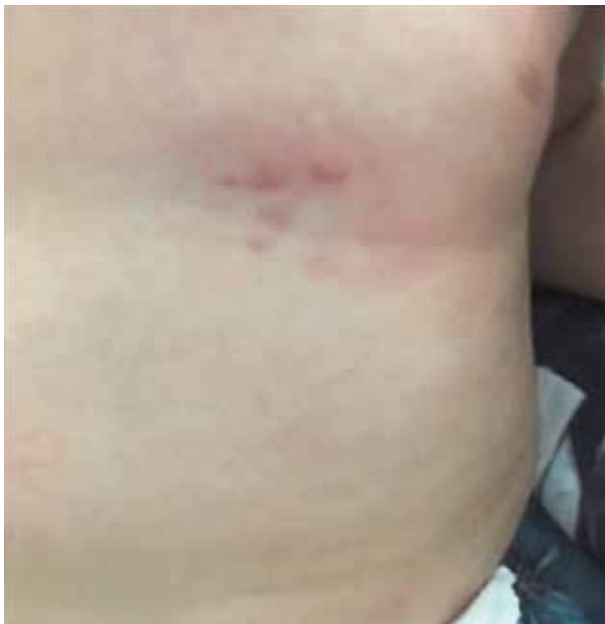

Figure 1. Lesions at 4 months old.

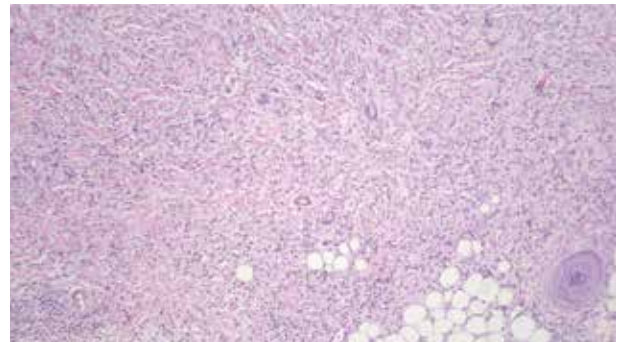


Figure 2. Infiltrate composed of foamy histiocytes and multiple scattered Touton-type multinucleated giant cells (hematoxylin and eosin, x100).

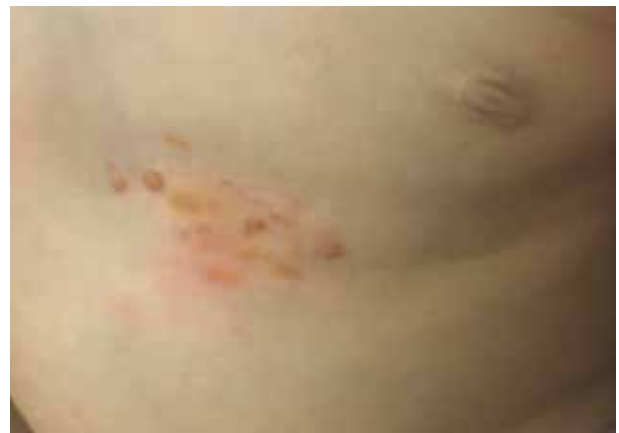

Figure 3. Lesions at 15 months old.

1. Pediatrics Department, Pediatric Hospital, Coimbra Hospital and University Center, Coimbra, Portugal

2. BRIOSA Family Health Unit, Norton de Matos Health Center, Coimbra, Portugal

3. Pediatric Dermatology Unit, Dermatology and Venereology Department, Pediatric Hospital, Coimbra Hospital and University Center, Coimbra, Portugal

Corresponding Author

Catarina Cordeiro

<https://orcid.org/0000-0002-9509-9378>

ana_catarina_cordeiro@hotmail.com

Av. Afonso Romão, 3000-602 Coimbra, Portugal

Received: 16/04/2020 | Accepted: 11/09/2020 | Published online: 15/03/2021 | Published: 03/04/2021

© Author(s) (or their employer(s)) and Portuguese Journal of Pediatrics 2021. Re-use permitted under CC BY-NC. No commercial re-use.

Keywords: Histiocytosis, Non-Langerhans-Cell/diagnosis; Infant; Xanthogranuloma, Juvenile/diagnosis

WHAT THIS REPORT ADDS

- Non-Langerhans cells histiocytosis is rare and requires a high level of suspicion for the diagnosis.
- Juvenile xanthogranuloma is on a spectrum of histiocytic disorders, which is necessary to differentiate from malignancies in childhood by way of a biopsy.
- Most of these lesions usually regress spontaneously and do not require any further therapeutic measures.

Conflicts of Interest

The authors declare that there were no conflicts of interest in conducting this work.

Funding Sources

There were no external funding sources for the realization of this paper.

Provenance and peer review

Not commissioned; externally peer reviewed.

Consent for publication

Consent for publication was obtained.

Confidentiality of data

The authors declare that they have followed the protocols of their work centre on the publication of patient data.

Acknowledgments

The authors would like to thank Dr. José Carlos Cardoso (Dermatology Service, Centro Hospitalar e Universitário de Coimbra) for providing the images and detailed description of the skin biopsy.

References

1. Chauhan S, Diwaker P, Singh A, Gogoi P, Arora VK. Cytological diagnosis of juvenile xanthogranuloma: A rare histiocytic disorder. *Diagn Cytopathol* 2020;48:66-70. doi: 10.1002/dc.24310.
2. Classen CF, Minkov M, Lehrnbecher T. The non-Langerhans cell histiocytoses (rare histiocytoses): Clinical aspects and therapeutic approaches. *Klin Padiatr* 2016;228:294-306. doi: 10.1055/s-0042-109713.
3. Lang C, Maul JT, Krähenbühl L, Dimitriou F, Dummer R. Histiocytaire neoplasien im kontext der aktuellen klassifikation. *Hautarzt* 2019;70:691-9. doi: 10.1007/s00105-019-4460-2.
4. Pajaziti L, Hapçiu SR, Pajaziti A. Juvenile xanthogranuloma: A case report and review of the literature. *BMC Res Notes* 2014;7:174. doi: 10.1186/1756-0500-7-174.
5. Weitzman S, Jaffe R. Uncommon histiocytic disorders: The non-Langerhans cell histiocytoses. *Pediatr Blood Cancer* 2005;45:256-64. doi: 10.1002/pbc.20246.